Use of a Novel Silicone-Acrylic Drape With Negative Pressure Wound Therapy in Anatomically Challenging Wounds

Luis G. Fernández, MD, FACS, FASAS, FCPP, FCCM, FICS[1]; Marc R. Matthews, MD, MS, FACS[2]; Carol Benton, BSN, RN, CWON[1]; Rebecca Buresch, BSN, RN, CWCN[1]; Angela Sutherland, BSN, RN, CWCN[1]; Natalie Tillison, RN[1]; Jenny Brooks, CNA, Wound Care Tech[1]

[1]University of Texas Health Science Center, Tyler, TX; University of Texas, Arlington, TX; University of North Texas, Fort Worth, TX; [2]Burn Emergency Services, Respiratory Care Services, Arizona Burn Center, Maricopa Medical Center, University of Arizona College of Medicine, Phoenix, AZ

Background

- Negative pressure wound therapy (NPWT*) utilizes a polyurethane drape with an acrylic adhesive† over foam dressings to create a seal.
- In anatomically challenging areas, it can be difficult to create a seal without the use of ancillary products.
- Additionally, healthcare providers are often unable to remove and reposition the drape once it has been placed.
- A novel hybrid drape (HA-drape‡) consisting of a polyurethane film with acrylic adhesive and a silicone perforated layer has been developed for use with NPWT to allow for repositioning after initial placement and easy removal.

Purpose

- This 6-patient case study reports on the use of the HA-drape with NPWT over anatomically challenging wounds.

Methods

- Three males and three females were treated with NPWT using the HA-drape.
- Dressing changes occurred every 2-3 days.
- Ease of application, repositioning, and ability to maintain a seal under negative pressure were evaluated by the healthcare providers following each dressing change.
- Intravenous and/or oral antibiotics were administered, if necessary.

Results

- Wound types treated included trauma, abdominal wall abscess, infected femoral popliteal bypass graft and site, transmetatarsal amputation, and below-the-knee amputation.
- Previous medical history included diabetes (type 1 and 2), hypertension, peripheral arterial disease, obesity, and chronic kidney disease (stage 4).
- Representative cases are shown in **Figures 1-3**.

Case Studies

Traumatic Wound. The patient presented for care with a traumatic wound (8.5 cm x 4 cm x 1 cm with a 2.5 cm tunnel) to the plantar surface of the right foot. Previous medical history included diabetes, hypertension, Klinefelter syndrome, neuropathy, peripheral artery disease, and polysubstance abuse. Sharp debridement was performed followed by application of NPWT with HA-drape.

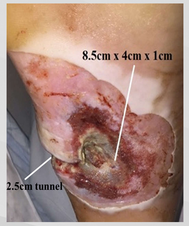

Figure 1a. Wound at presentation

Figure 1b. Application of NPWT with HA-drape (lateral view)

Figure 1c. Application of NPWT with HA-drape (plantar surface view)

Adominal Wall Abscess. The patient presented for care with left lower quadrant pain. Patient examination identified an anterior abdominal wall abscess with vesicocutaneous fistula. Previous medical history included stage 4 renal disease, urostomy, chronic metabolic acidosis, recurrent pancreatitis, and a previous abdominal surgery. The abscess was drained and NPWT with traditional drape was applied for 10 days, followed by transition to NPWT with HA-drape. The fistula was located outside of the drape field.

Figure 2a. Wound after removal of abdominal abscess

Figure 2b. Application of NPWT with HA-drape

Case Studies (Cont'd)

Infected Femoral Popliteal Bypass Graft and Site. The patient presented for care with an infected femoral popliteal bypass graft and site. The groin wound measured 6.5 cm x 3.8 cm x 4 cm and the left lower extremity wound measured 10 cm x 3 cm x 4.2 cm. Previous medical history included diabetes, hyperlipidemia, coronary artery disease, and peripheral artery disease. Oral antibiotics were administered followed by sharp debridement and application of NPWT with HA-drape.

Figure 3a. Wounds after sharp debridement (groin wound on left, left lower extremity wound on right)

Figure 3b. Application of NPWT with HA-drape

Figure 3c. Close up image of NPWT with HA-drape application on groin wound

Results (Cont'd)

- During NPWT application, the HA-drape was repositioned 1-2 times without any periwound skin irritation in a majority of wounds.
- Prior to the initial drape application, ancillary products such as skin prep ointment were applied to help create a seal.
  - However, by the second or third HA-drape application, healthcare providers were no longer using ancillary products in 4/6 wounds.
- Amount of HA-drape overlap used in 11/17 dressing applications across the 6 wounds was less than 3 cm.
- None of the dressing applications (with or without ancillary products) resulted in NPWT seal leaks.

Conclusions

- In these patients, healthcare providers were able to:
  - Reposition the HA-drape upon initial placement without periwound skin irritation.
  - Successfully create a negative pressure seal without the need of ancillary products in anatomically challenging wound locations.

Presented at Symposium on Advanced Wound Care/Wound Healing Society: A Virtual Experience, July 24-26, 2020

NOTE: Specific indications, contraindications, warnings, precautions and safety information exist for these products and therapies. Please consult a clinician and product instructions for use prior to application. Rx only.

As with any case study, the results and outcomes should not be interpreted as guarantee or warranty of similar results. Individual results may vary depending on the patient's circumstances and condition.

*V.A.C.® Therapy System with V.A.C.® GRANUFOAM™ Dressing, †V.A.C.® Drape, ‡DERMATAC™ Drape (KCI, San Antonio, TX)

The authors thank 3M for poster preparation and production.
Dr. Fernandez is a consultant to 3M Company.

© 2021 3M. All rights reserved. 3M and the other marks shown are marks and/or registered marks. Unauthorized use prohibited. PRA-PM-US-03386 (8/21)